

X: 1<sup>st</sup> RF-treatment ●: 2<sup>nd</sup> RF-treatment  
 X: 初回のRF治療 ●: 2回目のRF治療

Fig.1 図1

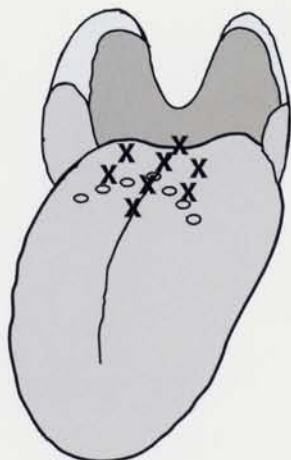
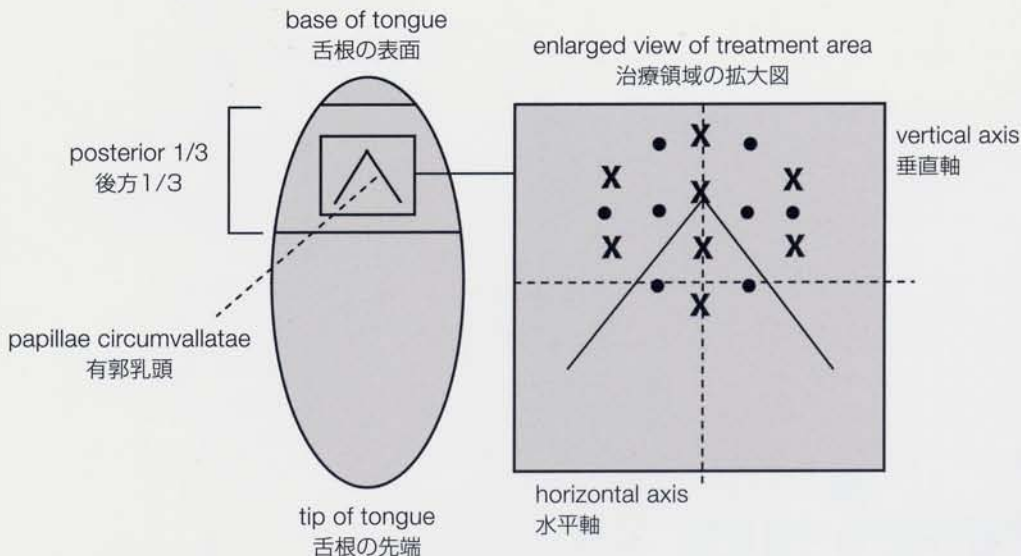


Fig.2 図2



(X): Puncture positions of the tongue base (root of the tongue) with CelonProSleep plus (first treatment session)

(o): Circumvallatae papillae

(X): CelonProSleep plusでの舌根(舌の根元)の穿刺位置(初回の治療セッション)

(o): 有郭乳頭

Puncture positions of the tongue base with CelonProSleep plus:

The positions are located in the area of the papillae circumvallatae. The coagulations are positioned in a distance of 0.75-1.0cm to each other, to ensure that a layer of native tissue remains between the coagulations. The time between two treatment sessions should be 6 weeks. It is important not to go further lateral than approx 1.5cm from the midline.

CelonProSleep plusでの舌根の穿刺位置:  
 穿刺位置は有郭乳頭領域内にある。凝固はたがい0.75~1.0cm離し、凝固間で本来の組織層が残るようにする。セッションとセッションの間は6週間あける。中央から約1.5cmより側面にいかないようにすることが重要です。

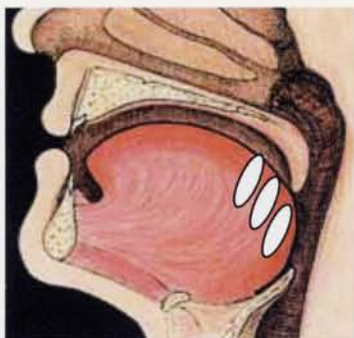
## Therapeutic effect:

治療効果:

The coagulations resulted in a volume reduction and stabilization of the tongue base.

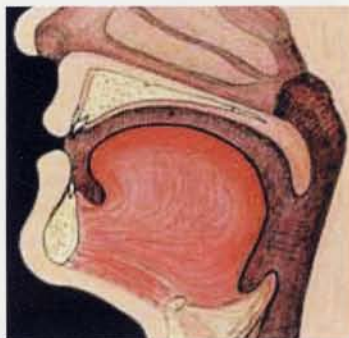
凝固により、舌根の容積減少と安定化が生じる。

Fig.3 図3



Position of the coagulations in the enlarged and slackened tongue base  
 肥大し、弛緩した舌根での凝固位置

Fig.4 図4



Volume reduction and stabilization of the tongue base after treatment  
 肥大し、弛緩した舌根での凝固位置